

## Diseases and parasites of laboratory reared and wild population of banded pearl spot *Etroplus suratensis* (Cichlidae) in Goa

Parveen Rattan

College of Fisheries, Shirgaon, Ratnagiri 415 629, Maharashtra, India

and

A. H. Parulekar

National Institute of Oceanography, Dona Paula, Goa 403004, India

Banded Pearl spot *Etroplus suratensis*, the inhabitant of coastal backwaters and lagoons is one among the few finfish species identified for brackishwater farming. Common diseases and parasites from the wild population of Goa and from the laboratory reared fish are described. The study revealed that the fin-rot disease and *Ancyrocephalus* sp. infestation can lead to heavy losses in confined systems.

The members of the family cichlidae are well known among the ichthyologists and aquaculturists, as evident from the wide distribution and cultivation of African species all over the world. *Etroplus suratensis* (Bloch, 1785) the only native representative of this family from the Indian subcontinent, has promising culture potential. This species has wide acceptability and is even considered as delicacy in certain regions. However, the culture status of this species is still at traditional level. From, aquaculture point of view, besides the information on food and feeding, reproductive biology and environmental requirements of a candidate species, the knowledge of timely disease diagnosis and therapy is equally important. In the present study, an attempt has been made to describe the common diseases and parasites of *E. suratensis* from the wild population as well as from the laboratory reared fish.

### Materials and Methods

Fishes ranging in size from 85 to 165 mm, were collected on five occasions from the backwaters of Goa (lat. 14° 54' - 15° 48' N & long. 73° 41' - 74° 21' E). In the laboratory, stocking density was maintained at the rate of 20 numbers/m<sup>3</sup> in the fibre glass tanks of 1500 litre capacity. Each time 4-5 specimens were observed to be infected with

fin-rot disease within a period of five days after stocking. The affected part of the caudal peduncle was removed, homogenized in normal saline and plated on nutrient agar to investigate the etiology. Poured plates were incubated in ambient condition with room temperature ranging from 27 to 31°C. A few colonies were picked up, purified and screened for important groups of bacteria following standard methods<sup>1</sup>. The infected fish were treated with a commercial anti-bacterial agent sold under the trade name of "Furacin" (Eskayef Ltd, Bangalore) at the rate of 0.4 to 0.5 mg/l of nitrofurazone for three successive doses on alternate days.

Heavy infestation of monogenean parasite in the gill filaments leading to 100 % mortality was experienced on one occasion in the laboratory reared fish. Mass mortality in the wild stock of brackish water fish at Curtorim and Siridao in Goa was recorded during the monsoon season of 1993. Incidentally, *E. suratensis* was also observed to have ulceration among the affected species. Moribund fish thus collected were studied for the body ulceration. The detailed study pertaining to skin, gill and fin parasites of wild population of *E. suratensis* was carried out on 205 specimens ranging in total length from 85 - 165 mm. About 1002 hosts were screened to record the incidence

of occurrence of isopod parasites which were later identified<sup>2-7</sup>.

## Results and Discussion

### *Fin-rot disease*

*Etroplus suratensis* was observed to be highly susceptible to fin-rot infection specially of caudal fin when reared in captivity. In the wild habitat as well as in the culture ponds, the species is found in a shoal of 6-25 numbers, however in culture tanks or in confined systems it develops territorial instinct and nibbling habit leading to skin or fin injury. Initially, the peripheral area of the caudal fin membrane gets eroded, which further progresses towards the caudal peduncle (Fig. 1). This progression of erosion later spreads towards dorsal, anal and pectoral fins within a couple of days. Regarding the behavioural aspect, fish becomes inactive with folded fins and prefers to hide near the bottom. After preliminary screening, the isolated bacterial colonies showed the dominance of gram negative rods of *Vibrio*, *Pseudomonas* and *Aeromonas* spp. The infected fish recovers from the trauma after the application of furacin and starts moving freely within a couple of days. The eroded fins get regenerated within 7-10 days.

### *Epizootic ulcerative syndrome (EUS)*

Besides *E. suratensis*, the other fish species affected with EUS were *Mugil cephalus*, *Arius* sp., *Ambassis commersoni*, *Diodon* sp., *Therapon jarbua*, *Puntius* sp., *Glossogobius* sp., *Scatophagus* sp. and *Siganus* sp. The incidence of EUS was as high as 90% in the estuarine habitat of Curtorim and Siridao in Goa, whereas the northern part of Goa was free from the epizootic infection. The prevalence of the disease coincided with the onset of southwest monsoon (June-September), when the water in the backwater area with reference to salinity was limnetic or freshwater. The prevalence of disease was only for a period of one month and later subsided by the end of monsoon, with increase in the salinity.

The lesions with necrotic tissue and red patches were observed in the head region and lateral parts of the body (Fig. 2). Few fish samples were still in moribund state inspite of severe ulcerative conditions and eroded jaws. The gut was found to

be empty and most of the visceral parts were heavily ulcerated.

*Trichodina* sp.: Only one type of organism was recorded from the wild population and the incidence of infestation was low to the tune of 2.45%. Parasite was detected in the gill filaments in low intensity (5 to 10 no. per gill arch) in all the hosts except one where the number was in hundreds. The parasite was identified as a 'Ciliate'. Hemispherical body and distinctive internal ring of denticles places this parasite under the order Peritrichia and the suborder Mobilina. The adoral spiral of approximately 360° and shape of denticles places this parasite under the genus *Trichodina* sp.

*Ancyrocephalus* sp.: A member of the monogenea group *Ancyrocephalus* sp. (Fig. 3) was observed to infest the gills of *E. suratensis*. In wild population, the incidence of infestation recorded was 1-5 numbers per gill arch. The incidence of parasite infestation in the laboratory reared host was absolute and the intensity was as high as 30 - 90 numbers per gill arch. The fish became inactive, remained at the surface, gasping and indicating respiratory stress. Opercula appeared to be somewhat open. The colouration of gills turned pink rather than the original brick red and the edge of gill filaments had grayish colouration. The gill filaments appeared clotted and necrotic. Overall colour of the host turned dark and the fish became sluggish.

*Caligus* sp.: Three copepod parasites were recorded from the branchial chamber of three separate hosts of the wild population indicating a very low level of intensity of infestation. The incidence of infestation was 1.46%. All the three parasites recorded were females characterised by flask shaped genital segment.

*Cymothoa krishnai* : Four pairs of isopod parasites were recorded from the buccopharyngeal cavity of the host. The striking feature was that the parasites were recorded in the form of male and female pair in a single host. Female was distinctly larger in size than the male (Fig. 4).

*E. suratensis* is highly susceptible to fin rot disease as evident from the present observations. Higher incidence of fin-rot infection and mortality has been observed when the seed of *E. suratensis* was transported from Ratnagiri to Bombay (A.K. Reddy, CIFE, Bombay personal communication). Fin-rot disease has also been reported




Fig. 1—Eroded caudal fin showing signs of fin-rot disease in *E. suratensis*.

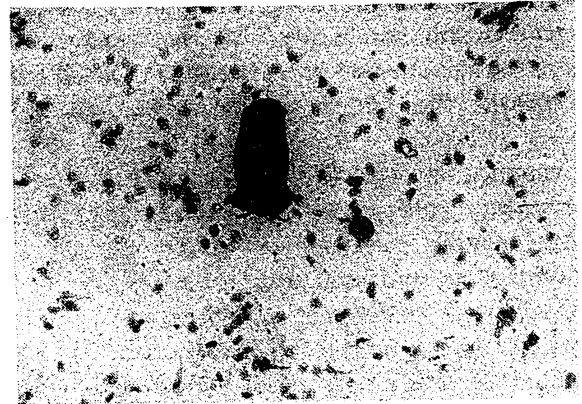


Fig. 3—Photomicrograph of a monogenean parasite *Ancyrocephalus* sp. (size 95.75  $\mu$ ).



Fig. 2—EUS affected fishes showing lesions and ulcerations over the body (size 80 - 110 mm)

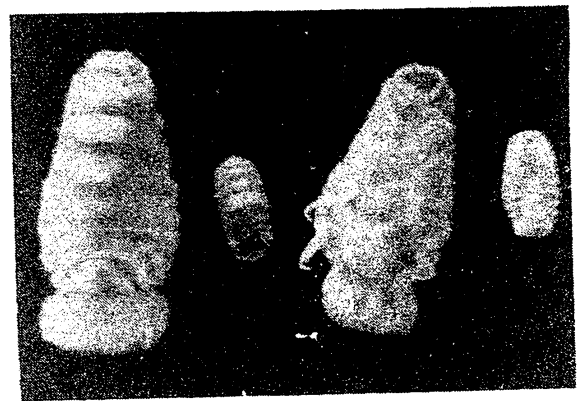


Fig. 4—Isopod parasite *Cymothoa krishnai*, female (larger, size 18.0 - 19.25 mm) and male (smaller, size 7.0 mm)

by Brightsingh *et al.*<sup>8</sup> while attempting to rear *E. suratensis* in an aquarium. They found the dominance of *Pseudomonas*, *Vibrio*, *Aeromonas*, *Bacillus* and *Carynebacterium* as associated flora. The specific pathogenesis of bacteria causing fin-rot has been reported<sup>8-12</sup>. In a study on fin-rot disease in brook trout *Salvelinus fontinalis*, Bullock<sup>13</sup> suggested that the primary cause of bacterial invasion is the lesion resulting from nutritional deficiency, injury and other predisposing factors. Thus, the incidence of eruption of fin-rot disease during the first few days of confinement could be due to injury during transportation, handling, nibbling etc., which provides a route of entry to the opportunistic *Vibrio*, *Pseudomonas* and *Aeromonas* species.

Nitrofurazone is effective in controlling the fin-rot disease in *E. suratensis* and can be practised to prevent the fish loss. Nitrofurazone has been reported to be a general disinfectant, however, it can not control systemic infection<sup>14</sup>. Further, it

does not interfere negatively with tissue regeneration<sup>15</sup>. Fin-rot disease in *E. suratensis* may be a superficial epidermal infection and can lead to systemic infection in due course of time. The fast regeneration of fin could be an added advantage of the use of nitrofurazone as a therapeutic agent. Hence, furacin can be used as a prophylactic measure and to control the fin-rot disease in culture systems, provided the diagnosis is done before it could attain the stage of systemic infection.

The outbreak of epizootic ulcerative syndrome has been reported earlier from different parts of India<sup>16-18</sup> as also from Asia Pacific region<sup>19-22</sup>. The pattern of dissemination of epizootic syndrome (1988 - 89 in north-eastern states and West Bengal in India, 1990 in Sri Lanka, 1991 in Kerala and 1992-93 in Karnataka<sup>23</sup> and Goa) indicates that the disease outbreak occurred first in the north-eastern states and later spread down to the south along the east coast, followed by an upward trend along the

west coast of India. Though the primary etiological agent is still not known, different workers have isolated bacteria and virus from the infected fish<sup>23</sup>. Recently, the fungal species *Aphanomyces* has been isolated<sup>18,24</sup> from the EUS infected fish. Generally, most of the fish pathogenic fungi are secondary pathogens<sup>23</sup>, and synchrony of season and natural outbreak could be due to the environment and viral complex necessary for the invasion of pathogenic aphanomycetes. In Goa waters, the prevalence of disease was only for a period of one month when it was almost fresh water (< 1‰ salinity) and the pH was between 6.8-7.2. The disease outbreak subsided by the end of monsoon with the simultaneous increase in salinity and pH. There is no further report of epizootic from the earlier affected areas, indicating that in a couple of years, the local fish fauna develops resistance to the disease. In natural waters, no prophylactic measures could be adopted, though in culture systems the application of lime at the rate of 600 kg/h in three instalments has been recommended<sup>12</sup>.

*Ancyrocephalus* sp. infestation in culture systems is a matter of serious concern, as in confined system in comparison to wild, the incidence and intensity of infestation is high by many folds, culminating in mass mortality. In this regard further studies with reference to life cycle, prophylactic and control measures are needed. The extent of damage caused by *Trichodina* sp. to *E. suratensis* could not be ascertained from the present study since the information was recorded from the wild stock. *Caligus* sp. and *Cymothoa krishnai* were recorded in very low intensity and from the incidence of infestation, it does appear that the extent of damage by this parasite to the fish species may not be severe. *Trichodina* sp., *Caligus* sp., and *C. krishnai* are the new records for *E. suratensis* and also to the estuarine habitat of Goa.

#### Acknowledgement

Authors are thankful to Dr. S. Jayadev Babu, Sir

Theagaraja College, Madras, for identifying the isopod parasites.

#### References

- 1 Buchanan R E & Gibbons N E, (Eds) *Bergey's manual of determinative bacteriology*, Williams and Wilkins, Baltimore, USA, 1974, pp. 1228.
- 2 Gussev A V, *Bull Fish Res. Sin Ceylon*, 16 (1963) 53.
- 3 Babu S J & Raj P J S, in *Proceedings of the symposium on coastal aquaculture Part - 3 Finfish culture*, (Marine Biological Association, Cochin, India) 1985, 818.
- 4 Kabata Z, *Parasites and diseases of fish cultured in tropics* (Taylor and Francis Ltd, London) 1985, pp. 318.
- 5 Pillay N K, *J Mar Biol Asso India*, 5 (1963) 68.
- 6 Pillay N K, *J Bom Nat Hist Soc*, 60 (1963) 665.
- 7 Tripathi Y R, *Indian J Helminth*, 9 (1957) 1.
- 8 Brightsingh I S, Lakshmanaperumalsamy P & Chandramohan D, *Bull Dpt Mar Sci Uni Cochin*, 12 (1981) 147.
- 9 Mahoney J B, Midlige F H & Deuel D J, *Trans Am Fish Asso*, 102 (1973) 596.
- 10 Karunasagar I, Ali P K M M & Jeyasekaran G, *Curr Sci*, 55 (1986) 1194.
- 11 Karunasagar I, Segar K, Ali P K M M & Jeyasekaran G, in *Recent advances in biotechnology and applied biology*, edited by S Chang, K Chan & N Y S Woo, (Chinese University, Hongkong) 1988, 205.
- 12 Kumar D, Day R K & Sinha A, in *Aquaculture productivity*, edited by V R P Sinha & H C Srivastava, (Oxford and IBH Publ Co, New Delhi) 1991, 345.
- 13 Bullock B I, *Prog Fish Cult*, 30 (1968) 19.
- 14 Colorni A & Paperna I, *Aquaculture*, 35 (1983) 181.
- 15 Kubota S S & Hagita K, *J Fac Fish Project Univ Mie*, 6 (1963) 125.
- 16 Anonymous, *CMFRI Newsletter*, 54 (1991) 1.
- 17 Kumar D, Farkas J & Sinha V R P, *Aquaculture Hungarica*, 5 (1986) 107.
- 18 Mohan, C V & Shanker M, *Curr Sci*, 66 (1994) 656.
- 19 Anonymous, in *Gaye tehnik bogor*, (Centre Bureau of Statistics, Ministry of Agriculture and Ministry of Trade, Indonesia) 1981, pp. 128.
- 20 Rogers L J & Burke J B, *J Fish Dis*, 4 (1981) 297.
- 21 Roberts R J, Macintosh J, Tonguthai K, Boonyaratpalin S, Tyaputch N, Phillips M J & Miller S D, *Field and laboratory investigations into ulcerative fish diseases in the Asia Pacific region*. TCP/RAS/4508 (FAO, Bangkok) 1986, pp. 214.
- 22 Anonymous, *Fishing Chimes*, 8 (1988) 74.
- 23 Roberts R J & Frerichs G N in *Recent advances in aquaculture*, Vol 5, edited by J F Muir & R J Roberts (Blackwell, London) 1994, 207.
- 24 Roberts R J, Willoughby L G, Chinabut S & Tonguthai K, *J Fish Dis*, 16 (1993) 169.