

Ammonium sulphate induced stress related alterations in the respiratory epithelium of the airbreathing organ of the catfish *Heteropneustes fossilis* (Bloch)

V I PAUL and T K BANERJEE*

Histochemistry and Histopathology Laboratory, Centre of Advanced Study in Zoology, Banaras Hindu University, Varanasi 221 005, India

MS received 5 October 1995; revised 8 April 1996

Abstract. In this paper, histopathological changes in the inner lining of the accessory respiratory organ of *Heteropneustes fossilis* following exposure to sublethal concentration (0.2 g l^{-1}) of ammonium sulphate (3 mg l^{-1} total ammonia-N) has been described. The goblet cells show periodic increased followed by decreased secretory activities. Necrosis and shedding of the epithelial cells over the secondary lamellae cause periodic haemorrhages which lead to degeneration and decreased number of secondary lamellae. Subsequently regeneration takes place each time as evidenced by the appearance of inflammatory tissue. Fusion of more than one secondary lamellae is also common. Regeneration also leads to uncontrolled hyperplasia of haphazardly arranged epithelial cells. This hyperplasia causes increased distance of respiratory blood-air barrier in the secondary lamellae, leading to impaired normal aerial respiration.

Keywords. *Heteropneustes fossilis*; accessory respiratory organ; ammonium sulphate toxicity; histopathology.

1. Introduction

Gills, skin, liver, kidney, thyroid, intestine and gonads are among the few extensively studied organ systems of fishes, exposed to various concentrations of ammonia (both NH_3 and NH_4^+) (Mukherjee and Bhattacharya 1975; Sathyanesan *et al* 1978; Smith and Piper 1975; Joy and Sathyanesan 1977; Chatterjee and Bhattacharya 1983; Thurston *et al* 1984; Ram and Sathyanesan 1986, 1987a; Bhattacharya *et al* 1989; Wright *et al* 1989; Banerjee and Paul 1993). Contamination of waterbodies with ammonia takes place during applications of the inorganic fertilizer, ammonium sulphate, both for agricultural as well as aquacultural purposes (Jhingran 1983; Ram and Sathyanesan 1987b; Sarkar 1991; Varadachari 1992). The live fish *Heteropneustes fossilis* (Bloch), an important edible catfish is a bimodal breather because it can respire aerially by gulping in air at various intervals when oxygen content of water is reduced below saturation point (Munshi 1993). A pair of sac-like backward extensions from the supra branchial chamber (derived from the embryonic gill mass), embedded deeply into the body myotomes, one on each side of the body are the main parts of the air breathing organs (accessory respiratory organ, ARO) in this fish (Munshi 1962, 1993) which unlike gills, does not come under the direct contact of the external medium. Hence in this paper, efforts have been made to analyse the toxicity of sublethal concentration of

*Corresponding author (Fax, 0542-312059).

ammonium sulphate on the inner epithelial lining (respiratory epithelium) of the ARO of *H. fossilis* because the toxic manifestation of the xenobiotics is affected in this vital organ via the circulatory system.

2. Materials and methods

2.1 Fish and their maintenance

Healthy specimens of *H. fossilis* of either sex belonging to a single population (body length 16–18 cm and body weight 35–40 g), collected at Varanasi were maintained in large plastic aquaria bearing 50 l of tap water for one month for acclimation. They were fed with minced goat liver on every alternate day. Water was renewed after every 24 h.

2.2 LC_{50} calculation

Prior to the commencement of the experiment, 96 h median lethal concentration (96 h LC_{50}) of ammonium sulphate (99% pure, E Merck India Ltd., Bombay) was estimated following trimmed Spearman Karber method (Hamilton *et al* 1977) and 24 h renewal bioassay system, which was found to be 2 g l^{-1} after 5% trimming.

2.3 Experimental protocol

Five groups of ten fish each were exposed to 50 l of 0.2 g l^{-1} (10% of the 96 h LC_{50}) ammonium sulphate (3 mg l^{-1} total ammonia nitrogen) (APHA *et al* 1985) solution prepared in tap water (having dissolved oxygen 6 mg l^{-1} , pH 7.5, hardness 23.2 mg l^{-1} and water temperature $26 \pm 2^\circ\text{C}$). Parallel controls under similar conditions but without the addition of ammonium sulphate were also maintained. Both the media (experimental as well as control) were renewed after every 24 h. Feeding was allowed for a period of 2 h on every alternate day before the renewal of the media. No mortality was observed at any stage of exposure.

2.4 Histopathological analysis

Five experimental and five control fish were sacrificed by cervical dislocation after the expiry of 5, 10, 20, 30 and 45 days of exposure. One cm long fragments of the ARO from the anterior end were fixed in 10% neutral formalin, aqueous Bouin's fluid and Helly's fluid. Permanent whole mount preparations as well as $6 \mu\text{m}$ paraffin sections were stained with Ehrlich's haematoxylin/eosin for general toxico-pathological analysis. Glycoproteins were localized by alcian blue pH 2.5 (AB 2.5) (Pearse 1985) and periodic acid Schiff (PAS) (McManus 1946) and AB 2.5/PAS dual staining (Pearse 1985). Sulphated acidic mucopolysaccharides were localized by alcian blue pH 1.0 (AB 1.0) (Lev and Spicer 1964). Bismarck brown technique was employed for water stable mucoproteins (Leech 1947). PAS with prior treatment with salivary amylase was used to confirm the presence of glycogen (Pearse 1985).

3 Results and discussion

3.1 Control accessory respiratory organ

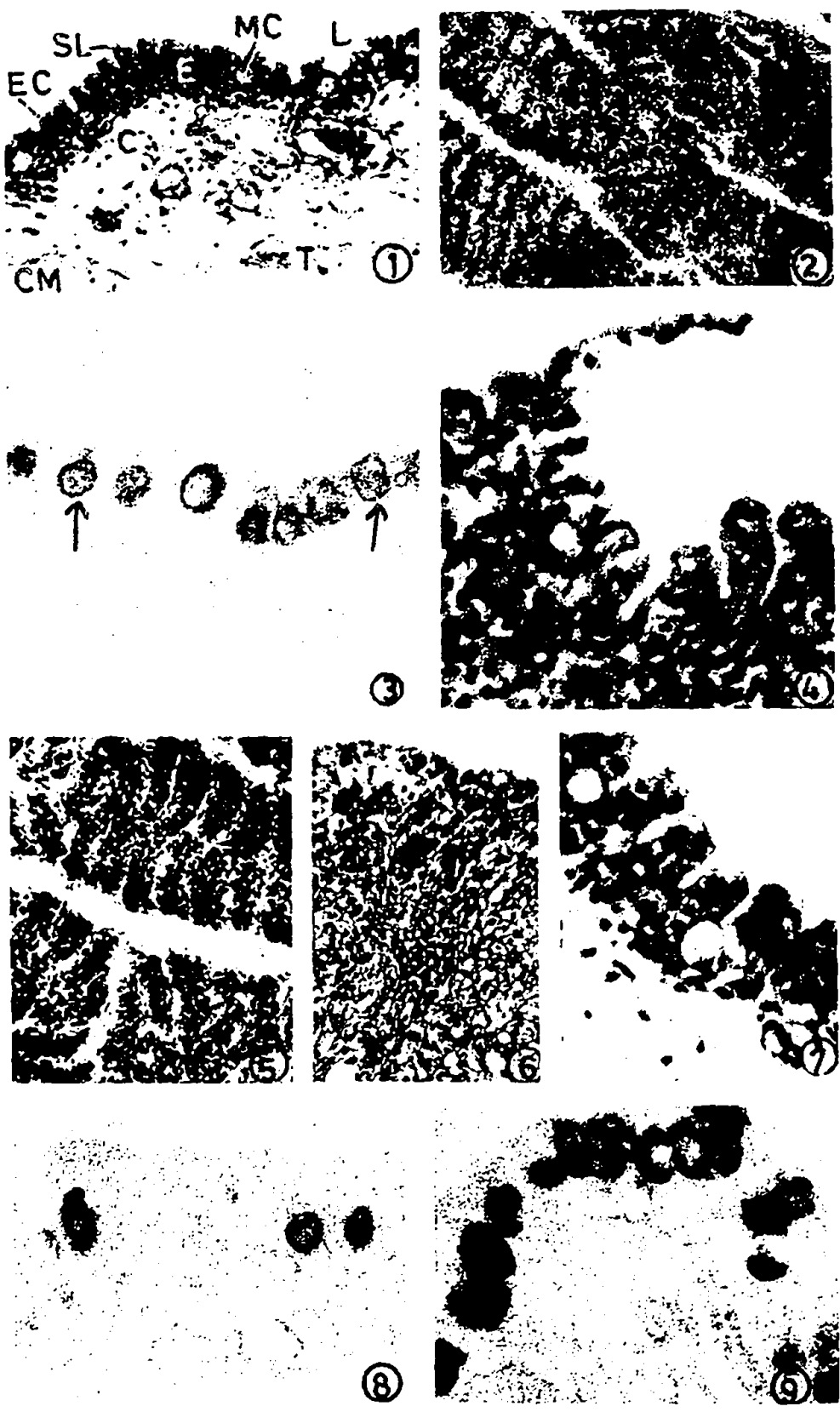
The innermost lining of the thin walled ARO of *H. fossilis* is a multilayered epithelium, next to which serially arranged are basement membrane, connective tissue layer, a thin membrane and a thin muscular coat (figure 1). Vascular and non-vascular areas constitute the inner epithelial lining. The vascular areas are represented by islets of secondary lamellae of various dimensions (Munshi 1962) (figure 2). An islet (primary lamellae) is formed by double row of modified secondary gill lamellae that hang into the lumen of ARO. In transverse sections (TS) these secondary lamellae appear as vertical strands penetrating perpendicularly into the multilayered epithelium (figure 3). Often in TS, these lamellae bulge out into the lumen as finger-like projections. In whole mount preparations the tips of the secondary lamellae appear to project into the lumen. Each secondary lamellae is made up of stacks of serially arranged pillar cells (figure 1). In between the pillar cells definite blood channels are formed. The non-vascular area of the epithelial lining is made up of several layers of epithelial cells (ECs) in between which are lodged a number of large sized mucous cells (MCs) (figure 3). A thin slimy layer of PAS negative and AB 2-5 positive material occasionally covers the inner surface at certain places. The moderately PAS positive basement membrane courses into the epithelium along with the secondary lamellae (figure 3).

3.2 Experimental accessory respiratory organ

Five days after exposure the density (number) of MCs decreases and the finger like secondary lamellae bulge out distinctly, projecting prominently into the lumen of the ARO (figure 4). The basement membrane of the epithelium and secondary lamellae stain markedly with PAS technique. The distal ends of the swollen banana shaped secondary lamellae bulge out further to acquire club shape which also get engorged with red blood cells. At certain places, the epithelial lining becomes degenerate and sloughs off (figure 4). Focal inflammatory tissues which represent sites of active healing and re-differentiation of lamellar structures, are noticed at this stage of exposure. Similar inflammatory foci (granulation tissues) were also observed at the healing sites of superficial skin wounds by Mittal and Munshi (1974) and Mittal *et al* (1979). Even though the blood capillaries stain prominently with PAS, the inflammatory tissue stains negatively for glycoproteins and other acidic mucosubstances. Minute developing MCs are occasionally noticed in the regenerating epithelial tissue over the inflammatory tissue. A few fine glycogen granules are also noticed in the undifferentiated inflammatory tissue.

With AB 2-5, the intensity of reaction in MCs decreased markedly up to 20 days of exposure. The intensity, however, increases after 30 days and with further treatment, when the entire volume of the MCs stained strongly. After 10 days, the inflammatory tissue disappears probably due to completion of regeneration following differentiation of various elements of the damaged ARO. The newly regenerated epithelium shows hyperplasia of haphazardly arranged ECs with poorly formed secondary lamellae (figure 5).

Regeneration of secondary lamellae continues after 20 days with swelling again to become prominent. Fusion of more than one secondary lamellae are commonly



Figures 1 - 9.

observed along with the accumulation of blood at the tips of the club-shaped secondary lamellae. Similarly, prominent inflammatory tissues are again observed in the subepithelial area after 30 days of exposure (figure 6). Re-appearance of the inflammatory tissue after 30 days suggests active process of healing of certain severely damaged areas on the inner lining of the air-sac. The highly vascular inflammatory tissue in the subepithelial region below the newly regenerated epithelium is marked by the presence of numerous red blood corpuscles (RBCs). Well defined (regenerated) blood capillaries to enclose the RBCs are not properly located. However, secondary lamellae are observed in undamaged epithelia during this period of exposure. After 45 days these lamellar structures become well formed and prominently exposed. Side by side shedding of ECs causing haemorrhage and leaking of blood into the lumen and fusion of secondary lamellae (figure 7) are again noticed due to continuation of treatment.

Like the acute ammonia exposure (Paul and Banerjee 1995), the density and staining properties of MCs during the present investigation also exhibit periodic fluctuations (figures 8, 9 and table 1). At different stages of exposure, periodic fluctuations in the quantity of glycogen granules are also observed (table 1). There is a marked decrease in the quantity of glycogen after 10 days followed by an increase after 20 days. Thereafter the decreasing trend continues and disappear completely after 45 days.

Even though the ARO is not directly exposed, the periodic fluctuations observed in the secretory activity of MCs in the present study is more or less identical to those observed in gills and skin of fishes (Roy 1988; Roy *et al* 1993). Similar fluctuations have also been noticed in the MCs of ARO following treatment with toxic heavy metal salts (Rajan and Banerjee 1992; Hemalatha and Banerjee 1993). Although, the exact reason for the fluctuation is not properly understood especially when the ARO is not getting exposed directly to the xenobiotic, it might perhaps be due to the common origin of the ARO and the gills (Munshi 1993). The ARO also shows fusion of its secondary lamellae similar to those observed in gills following exposure to the ammonia solution (Smith and Piper 1975) as well as other toxicants (Leino *et al* 1987). Even though the ARO does not suffer the contact stress, erosion of the epithelial lining and alterations in the chemical composition of mucus are prominently observed in the ARO following ammonium sulphate exposure. This could perhaps be the reason for fusion of secondary lamellae. Because, according to Daoust *et al* (1984) the lamellar adhesion in gills might be due to contact stress which causes erosion and consequent alteration in the

Figure 1–9. (1) T S of the ARO of control fish showing its structural organization and the arrangement of various tissue layers. H/E; X164. (C, connective tissue; CM, cucularis muscle; E, epithelium; EC, epithelial cells; L, lumen; MC, mucous cell; SL, secondary lamellae; T, thin membrane). (2) Whole mount (WM) preparation showing the normal distribution of respiratory islets (bearing SL) H/E; X164. (3) T S showing the distribution of MCs (arrows) in the epithelium of the ARO of control fish. Note the positively stained basement membrane of the general epithelium as well as those lining the secondary lamellae. AB 2.5/PAS; X738. (4–9) Toxicopathological effects of sublethal concentration of ammonium sulphate on the ARO. (4) T S showing prominently exposed SL projecting distinctly into the lumen after 5 day of exposure. Note the swollen distal ends of the SL acquiring club shape and sloughing of the damaged supporting cells. H/E; X738. (5) W M showing hyperplasia of haphazardly arranged ECs following regeneration after 10 day of exposure. Note the fusion of SL. HE; X738. (6) T S showing regeneration of SL (arrows) from the inflammatory tissue mass after 30 day of exposure. H/E; X738. (7) T S showing fusion of SL after 5 day of exposure. H/E; X738. (8) T S showing decreased population of MCs after 5 day of exposure. AB 2.5/PAS; X738. (9) T S showing increased population of MCs after 45 day of exposure. AB 2.5/PAS; X738.

Table 1. A summary of histochemical alterations in the carbohydrate contents of respiratory epithelium of the accessory respiratory organ of *H. fossilis* at various time intervals of sublethal ammonium sulphate exposure.

Staining techniques	Cell type	Control	Experimental groups				
			5d	10d	20d	30d	45d
PAS for neutral glycoproteins (1,2 glycols)	ECs	0	0	0	0	0	
	MCs	3 + ^b 2 + ^c	3 + ^b 1 + ^c	3 + ^b 3 + ^c	3 + ^b 2 + ^c	3 + ^b 3 + ^c	
AB 1-0 for sulphated glycosaminoglycans	ECs	0	0	0	0	0	
	MCs	0	0	0	0	0	
AB 2-5 for acidic glycoproteins	ECs	0	1 +	0	0	0	
	MCs	4 + ^b 3 + ^c	2 + ^b 1 + ^c	2 + ^b 2 + ^c	3 + ^b 3 + ^c	3 + ^b 3 + ^c	
AB/PAS for acidic and neutral glycoproteins	ECs	0	1 + G	0	0	0	
	MCs	3 + P ^b 3 + P ^c	3 + R ^b 3 + R ^c	4 + B ^b 2 + G ^c	4 + B ^b 3 + G ^c	4 + B ^b 3 + G ^c 4 + L ^b 4 + L ^c	
BB for water stable mucoproteins	ECs	0	0	0	0	0	
	MCs	2 + ^b 2 + ^c	3 + ^b 3 + ^c	4 + ^b 1 + ^c	4 + ^b 4 + ^c	3 + ^b 2 + ^c 4 + ^b 2 + ^c	
PAS positive salivary labile glyco-	ECs	0	0	0	2 +	1 +	
	MCs	0	0	0	0	0	

AB 1-0, Alcian blue pH 1-0, AB 2-5, Alcian blue pH 2-5; BB, Bismark brown; ECs, epithelial cells; MCs, mucous cells; PAS, periodic acid Schiff; AB/PAS, Alcian blue pH 2-5/periodic acid Schiff; B, reddish green; b, cell periphery; c, cell contents; G, greenish blue; L, blackish red; P, bluish purple; R, dark red; 0, negative reaction; 1 +, weak reaction; 2 +, moderate reaction; 3 +, strong reaction; 4 +, very strong reaction.

chemical composition and thickness of the mucous layer after interaction with antibiotics. This disturbs the normal ability to recognize different cell types resulting in fusion of the secondary lamellae.

Formation of inflammatory tissue in the sub-epithelial layer at different stages of exposure indicates active and repeated healing and regeneration of lamellar elements from the severely damaged sites. This shows that severe toxicity has been rendered to the deeply embedded respiratory organ by the ammonia solution even at sublethal concentration causing disturbed aerial respiration. While studying the chronic toxicity of ammonia to Fathead Minnows (*Pimephales promelas*), Thurston *et al* (1986) also observed deep-seated mild to severe lesions of connective tissues (connective tissue hyperplasia), originating from the *Meningeal primativa*, covering the brain and termed it as proliferating tissue. Blood vessels were also observed throughout the proliferated tissue. These proliferated tissues also stained negatively for collagen, mucin and mucopolysaccharides (Smith 1984).

Acknowledgements

This work was supported by the University Grants Commission, New Delhi [Project No. P3-68/89 (SRII)]. VIP is thankful to the Council of Scientific and Industrial Research, New Delhi for financial assistance in the form of a Senior Research Fellowship.

References

- APHA (American Public Health Association), AWWA (American Water Works Association) and Water Pollution Control Federation 1985 *Standard methods for the examination of water and waste water* 16th edition (Washington DC: American Public Health Association)
- Banerjee T K and Paul V I 1993 Estimation of acute toxicity of ammonium sulphate to the freshwater catfish *Heteropneustes fossilis* II. A histopathological analysis of the epidermis; *Biomed. Environ. Sci.* **6** 45–58
- Bhattacharya T, Bhattacharya S, Ray A K and Dey S 1989 Influence of industrial pollutants on thyroid function in *Channa punctatus* (Bloch); *Indian J. Exp. Biol.* **27** 65–66
- Chatterjee S and Bhattacharya S 1983 Ammonia induced changes in the hepatic glutathione level of an air-breathing fresh water teleost *Channa punctatus* (Bloch); *Toxicol. Lett.* **17** 329–333
- Daoust P Y, Wobster G and Newsfad J D 1984 Acute pathological effects of inorganic mercury and copper in gills of rainbow trout; *Vet. Pathol.* **21** 93–101
- Hamilton M A, Russo R C and Thurston R V 1977 Trimmed Spearman Karber method for estimating median lethal concentration in toxicity bioassays; *Environ. Sci. Technol.* **11** 714–719
- Hemalatha S and Banerjee T K 1993 Acute toxicity of the heavy metal zinc (a trace metal) on the mucous cells of the air sac (a modified gill structure) of the air-breathing catfish *Heteropneustes fossilis* (Bloch); *J. Freshwater Biol.* **5** 233–240
- Jhingran V G 1983 *Fish and fisheries of India* (New Delhi: Hindustan Publishing Corporation) pp 1–666
- Joy K P and Sathyanesan A G 1977 Ammonium sulphate as a thyroid inhibitor in the fresh water teleost *Clarias batrachus* (L.); *Curr. Sci.* **46** 671–672
- Leech E H 1947 Bismarck brown as a strain for mucoproteins; *Stain. Technol.* **22** 73
- Leino R L, Wilkinson P and Anderson J G 1987 Histopathological changes in the gills of pearl dace *Semotilus margarita* and fathead minnows, *Pimephales promelas*, from experimentally acidified Canadian lakes; *Can. J. Fish. Aquat. Sci.* **44** 126–134
- Lev R and Spicer S S 1964 Specific staining of sulphated groups with alcian blue at low pH; *J. Histochem. Cytochem.* **12** 309
- McManus J F A 1946 Histological demonstration of mucin after periodic acid; *Nature (London)* **158** 202
- Mittal A K and Munshi J S D 1974 On the regeneration and repair of superficial wounds in the skin of *Rita rita* (Ham) (*Bagridae*, Pisces); *Acta Anat.* **88** 424–442

- Mittal A K, Rai A K and Banerjee T K 1979 Mucopolysaccharides during the healing of cutaneous wound of *Heteropneustes fossilis* (Bloch) (*Heteropneustidae*, pisces) A histochemical investigation; *Mikroskopie* **35** 265-274
- Mukherjee S and Bhattacharya S 1975 Histopathological lesions in the hepatopancreas of fish exposed to industrial pollutants; *Indian J. Exp. Biol.* **13** 571
- Munshi J S D 1962 On the accessory respiratory organs of *Heteropneustes fossilis* (Bloch); *Proc. R. Soc. Edinb.* **68** 128-146
- Munshi J S D 1993 Structure and function of the air breathing organs of *Heteropneustes fossilis*; in *Advance in fish research I* (ed.) B R Singh (Delhi: Narendra Publishing House) pp 99-138
- Paul V I and Banerjee T K 1995 Acute toxicity of ammonium sulphate to the air-breathing organ of the live fish *Heteropneustes (Saccobranchus) fossilis* (Bloch); *Curr. Sci.* **68** 845-849
- Pearse A G E 1985 *Histochemistry theoretical and applied* vol. II (New York: Churchill Livingstone Inc) pp 441-1055
- Rajan M T and Banerjee T K 1992 Acute toxic effect of mercuric chloride on the mucocytes of the epithelial lining of the accessory respiratory organ and skin of the air breathing catfish *Heteropneustes fossilis* (Bloch); *Biomed. Environ. Sci.* **5** 325-335
- Ram R N and Sathyanesan A G 1986 Ammonium sulfate induced nuclear changes in the oocyte of the fish, *Channa punctatus* (Bl.); *Bull. Environ. Contam. Toxicol.* **36** 871-875
- Ram R N and Sathyanesan A G 1987a Effect of chronic exposure of commercial nitrogenous fertilizer, ammonium sulphate on testicular development of a teleost *Channa punctatus* (Bloch); *Indian J. Exp. Biol.* **25** 667-670
- Ram R N and Sathyanesan A G 1987b Histopathological changes in liver and thyroid of the teleost fish, *Channa punctatus* (Bloch) in response to ammonium sulfate fertilizer treatment; *Ecotoxicol. Environ. Safety* **13** 185-190
- Roy D 1988 Statistical analysis of anionic detergent induced changes in the goblet mucous cells of opercular epidermis and gill epithelium of *Rita rita* (Ham) (*Bagaridae*, Pisces); *Ecotoxicol. Environ. Safety* **15** 260-271
- Roy U K, Gupta A K and Chakkrabarti P 1993 Deleterious effects of zinc on the skin of *Notopterus notopterus* (Pallas); *J. Freshwater Biol.* **5** 191-196
- Sarkar S K 1991 Use of ammonium sulphate nitrate in rearing major carp spawn; *Geobios* **18** 177-181
- Sathyanesan A G, Joy K P and Kulkarni R S 1978 Endocrine changes in fishes in response to pollutants; *Q. J. Surg. Sci.* **14** 67-77
- Smith C E 1984 Hyperplastic lesions of the primitive meninx of fathead minnows, *Pimephales promelas*, induced by ammonia: Species potential for carcinogen testing; *Natl. Cancer Inst. Monogr.* **65** 119-125
- Smith C E and Piper R G 1975 Lesions associated with chronic exposure to ammonia; in *The Pathology of Fishes* (eds) W E Ribelin and G Migaki (Wisconsin: The University of Wisconsin Press) pp 497-515
- Thurston R V, Russo R C, Meyn E L and Zajdel R K 1986 Chronic toxicity of ammonia to fathead minnows; *Trans. Am. Fish. Soc.* **115** 196-207
- Thurston R V, Russo R C, Luedtke R J, Smith C E, Meyn E L, Chakoumakos C, Wang K C and Brown C J D 1984 Chronic toxicity of ammonia on rainbow trout; *Trans. Am. Fish. Soc.* **113** 56-73
- Varadachari C 1992 Phosphoric acid, phosphates and fertilizers for the future; *Proc. Indian Natl. Sci. Acad.* **B58** 119-126
- Wright P A, Randall D J and Perry II S F 1989 Fish gill water boundary layer: a site of linkage between carbon dioxide and ammonia excretion; *J. Comp. Physiol.* **158** 627-635

Corresponding editor: SAMIR BHATTACHARYA