

ON THE OCCURRENCE OF ENDOPARASITES FROM COPEPODS OF THE WEST COAST OF INDIA

V. SANTHAKUMARI

Regional Centre, National Institute of Oceanography
Kochi - 682 018

ABSTRACT

Occurrence of endoparasitic dinoflagellates belonging to the genera, *Blastodinium*, parasitizing the coelomic cavity of their host, copepods was investigated. Infection by these species seems to be harmful to the host. Parasitized individuals showed striking morphological changes in shape and colour. The percentage of infection of these parasites is less on the west coast of India.

Key-words : Endoparasites, copepods.

The role of parasitism in fresh water copepod populations is known (Burns, 1980), while the impact on marine copepod communities is difficult to assess. Parasitism play an important part in controlling seasonal abundance cycles in coastal copepod populations in certain areas (Ianora, Mazzocchi and Carlo, 1987). At the individual level, parasitism can arrest development, induce intersexuality, cause sterility and even death of the host (Chatton, 1920). Observations on the presence of internal parasites are also given by With (1915), Steuer (1932), Sewell (1951), Vane (1952), Marshall and Orr (1955) and Corkett and McLaren (1978). The internal parasites of copepods from Arabian Sea especially from coastal waters is little studied. An attempt has been made to study the endoparasites of copepods from the south-west coast of India.

Zooplankton collections were made from the west coast, off Karwar and Ratnagiri, with the net of Bongo 60, made of nylon material of 0.5 mm mesh width (60 cm ring diameter) with calibrated flowmeter. The zooplankton samples were preserved in 4% formaldehyde solution in seawater. Samples were analysed from associates and parasites. Host specimens were placed on a cavity slide under a cover slip and examined under a binocular microscope. Drawings were made with the aid of a camera lucida.

Blastodinium chattoni Sewell, 1951

This parasite was observed in *Undinula vulgaris* and *Rhincalanus* sp. which were collected from Karwar and Ratnagiri.

Large sized parasites were seen in larger hosts. The whole parasite was long with dilation in the middle part. During the course of development, the superficial layer of sporocytes become darker than the inner layers (Fig. 1a): In some specimens the outermost cells of the second layer of sporocytes also showed the same change. The diblastic condition occurred in most of the specimens.

The infected copepods could be identified by their dark and chubby appearance, due to the pronounced swelling in the prosome with a maximum dilation at the posterior end of the cephalothorax. When probed with a dissecting needle each individual released a cloudy mass of dinospores. Only one parasite could be observed from a single host.

Blastodinium mangini Chatton, 1908

This was noticed in the gut cavity of *Labidocera* sp. collected from Ratnagiri coast. Only one parasite was found from a single host, whereas Sewell (1951) recorded several parasites from a single host. Eventhough thousands of specimens were examined, this parasite was found only twice.

These specimens showed slight variation in shape from that of Chatton's description. The anterior end of this species is broader than the posterior end (Fig. 1b). The parasite occupied the anterior region of the gut cavity of the host. In preserved condition it was seen in orange brown colour.

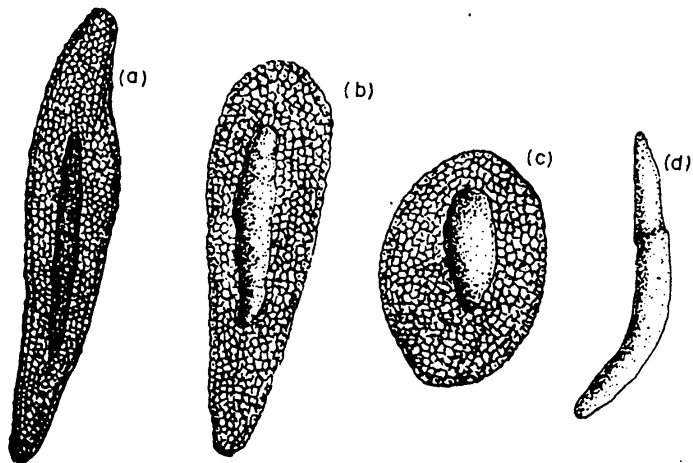


Fig. 1. (a) *Blastodinium chattoni* showing the structure, (b) *B. mangini*, (c) *B. oviforme*, (d) unidentified trophocyst of *Blastodinium* sp.

Blastodinium oviforme Chatton, 1912

This species was found in the gut cavity of *Eucalanus* collected from Ratnagiri coast. Chatton (1920) and Sewell (1951) recorded this species from *Oithona* and *Oncaea*. The general shape of this species varied from host species to species. In every instance only a single parasite was present in a host specimen (Fig. 1c).

An unidentified trophocyte (Fig. 1d) was observed from the posterior region of the alimentary tract of *Undinula vulgaris* collected from Karwar coast. This trophocyte differs from other described trophocytes. Only one specimen was obtained.

Inora, Mazzocchi and Carlo (1987) indicated that most of the copepod species were frequently infected by internal parasites in the Gulf of Naples. The degree to which the abnormalities are manifested in male and female hosts seem to depend on the developmental stage at which infection occurs with most profound effects arising from early infection. Infection rate was low in the present set of collections and the infection seem to be greater for juveniles as compared to females and was completely lacking in males. Though the infection by *Blastodinium* may not be fatal, it may produce harmful effects on host's reproductive system.

Larger *Blastodinium* species seems to induce sexual castration in their hosts by compressing the space occupied by the gonads thereby impeding their normal development. Jepps (1937) suggested that the ovaries of parasitized females contain irregular oocytes with degenerate nuclei. If intersexuality is an indirect expression of parasitism, the presence of male characters in adult females is attributable to masculinization in secondary sexual characters in developing females (Sewell, 1951).

ACKNOWLEDGEMENT

The author is grateful to the Director, National Institute of Oceanography, Goa for providing facilities.

REFERENCES

- Burns, C.W., 1980. Occurrence of *Aphanomyces ovidestruens*, a fungus parasitic on copepods, in two eutrophic lakes. *New Zealand Journal of Marine and Fresh Water Research*, 14: 23-29.
- Chatton, E., 1920. Les peridiniens parasites. Morphologie reproduction ethodogie.
- Corkett, C.J. and I.A. McLaren, 1978. The biology of *Pseudocalanus*. *Advances in Marine Biology*, 15: 1-231.
- Inora, A., M.G. Mazzocchi, and B.S. Carlo, 1987. Impact of parasitism and intersexuality on Mediterranean population of *Paracalanus parvus* (Copepoda - Calanoida). *Dis. Aquatic Organisation*, 3: 29-36.

- Jepps, M.W., 1937. On the protozoan parasites of *Calanus finmarchicus* in the Clyde Sea area. *Quarterly Journal of Microscopical Science*, 79: 589-658.
- Marshall, S.M. and A.P. Orr, 1955. *The Biology of a Marine Copepod Calanus finmarchicus (Gunnarus)*, Oliver and Boyd, Edinburg.
- Sewell, R.B.S., 1951. The epibionts and parasites of the planktonic copepods of the Arabian Sea. *John Murray Expedition Scientific Report. B.M. (N.H.)*, 9: 255-394.
- Steuer, A., 1932. Copepoda 6. *pleuromamma giebg* 1898. *Der Deutsche Tiefsee Expedition Valdivia, 1898-1899*, 24: 1- 119.
- Vane, F.R., 1952. The distribution of *Blastodinium hyalinum* in the North Sea. *Challenger Society*, 3: 23-24.
- With, C., 1915. Copepoda. 1. Calanoida Amphascandira. *Danish Ingolf Expedition*, 3: 1-260.