

## **Diseases and parasites in cultured yellow seahorse, *Hippocampus kuda* (Bleeker, 1852)**

S. V. Sanaye, H. B. Pawar, A. Murugan, R. A. Sreepada\*, Tanu Singh & Z.A. Ansari

**Aquaculture Laboratory, National Institute of Oceanography (NIO),  
Council of Scientific and Industrial Research (CSIR), Dona Paula – 403004, Goa, India**

---

### **Introduction**

The complex nature of aquatic ecosystem marked difference between health, suboptimal performance and disease obscure. Disease outbreak in aquaculture is an end result of a series of linked events which involving interaction between host, the environment and the pathogen (Snieszko, 1974). Environment includes not only the water and its components (such as oxygen, pH, temperature, toxins, wastes) but also the kind of management practices (e.g. handling, drug treatments, transport procedures, etc.). Recognition and prevention of disease is a challenge that has to be faced by aquaculture industry and it is important to dealing with available resources effectively.

As most of the cultured fishes, seahorses get stressed when kept at high densities and that stress makes them more vulnerable to infection. With the increasing interest in developing and standardizing the protocols for syngnathids aquaculture and its conservation, the information on the disease diagnostics plays significant roles in animal health management and disease control. Moreover, animal health studies in captive conditions helps in understanding the adequate information on solving husbandry problems. The success of closing the life cycle of seahorses under captive conditions will promote marine aquarium trade and export for traditional medicine which may open up new avenues for employment for coastal rural population. In addition, syngnathids aquaculture would reduce the fishing pressure on wild population and the developed technique can be used for species recovery programme. In most Asian countries, as well as in Australia, New Zealand, South Africa and in USA, commercial seahorse aquaculture technology development were/are underway (Vincent, 1996) and at present around 24 countries are involved in this venture (Koldewey and Martin-Smith 2010). The seahorse aquaculture is a relatively new industry for India will be addressing many culture related problem. Especially, the technical challenges remain notably in disease, nutrition and the development of species-specific culture techniques.

The observations on different diseases and parasitic infection were recorded at the pilot-scale seahorse hatchery adjoining the Aquaculture laboratory complex of the National Institute of Oceanography, Goa, where techniques for the standardization of captive breeding, rearing and culture of Indian seahorse species are being established. This article describes disease related

problems observed in culture and rearing of yellow seahorse, *Hippocampus kuda* (F1 and F2 generation) under captive conditions. It is expected that the information on diseases of this species would help in improving and optimize the syngnathids aquaculture in India.

### **Problems encountered in rearing of juveniles**

#### ***Gas bubble ingestion***

Ingestion of air bubble into the gut was found to be the major cause of mortality during pelagic phase juvenile rearing. Seahorse juveniles while preying on live food organisms (copepods nauplii, copepodites and *Artemia* nauplii, etc.) engulf the atmospheric air if they miss the strike and this leads to formation of air bubbles in the digestive tract. The early juveniles are unable to release out the ingested air bubbles. Seahorse juveniles with ingested air bubbles exhibit irregular swimming pattern, lose their balance and are unable to capture prey, subsequently leading to starvation and ultimately to death.



Fig. 1. Air ingestion by seahorse juvenile

#### ***Solution***

Appropriate feed density (>6 no. copepod nauplii/copepodites per ml) with dark colour background preferably blue can significantly decrease the false attack and air bubble ingestion. Our experiments on effect of background tank colour (Pawar *et al.*, 2011) on growth and survival in pelagic phase juveniles of the yellow seahorse suggested that dark background colour tanks provide better detection of prey and less chance of air bubble ingestion. In addition to that dissolved oxygen levels should be always more than 4 ppm with a minimum water movement helps in increasing survival and growth.

### **Problems encountered in rearing of adults**

#### ***External gas bubble disease (EGBD)***

Gas bubble disease is a non-infectious disease caused by environmental problems in the culture system. Supersaturated gases, not only oxygen but also nitrogen in the water, escape from the water

into the body fluids of the rearing fish. Gasses in supersaturated water will try escape out of the water into any medium where the gas saturation level is lower (e.g. into the air, or in the case of gas bubble disease, into the blood and other fluids of the fish). Most commonly they are encountered in the yolk sacs, gills and eyes (and occasionally in fins) as these are the areas of the body which have the most gas permeable membranes. The gas then causes bubbles to form inside capillaries and under the skin, restricting the blood flow and forming hemorrhages and clots. Although the disease often looks disastrous for the affected animal, in many cases the bubbles resolve with few problems for the affected fish. Though, it is non-infectious disease, the most common adverse outcomes are loss of an eye, bacterial infections of the lesions or brain damage.

External gas bubble disease (EGBD) may cause either due to gas super-saturation in the tank water or by bacterial infections where carbon dioxide produced by the bacteria becomes trapped underneath the skin. These subcutaneous (under the skin) air bubbles that may occur anywhere on the head, body, or prehensile tail of seahorse. The situation, wherein gas levels in the water are much higher than normally possible (caused by limited areas for gas escape), causes gas bubbles to form anywhere possible. Because the pressure inside of a seahorse is lower than the pressure of gas super-saturated water, the gas bubbles emerge directly under the skin of the affected seahorse. Since the air bubbles cannot pass through the skin, they remain stranded there until treated or until they can be reabsorbed by the seahorse's own body. The bubbles can cause stress on a seahorse as problems with buoyancy and movement arise.

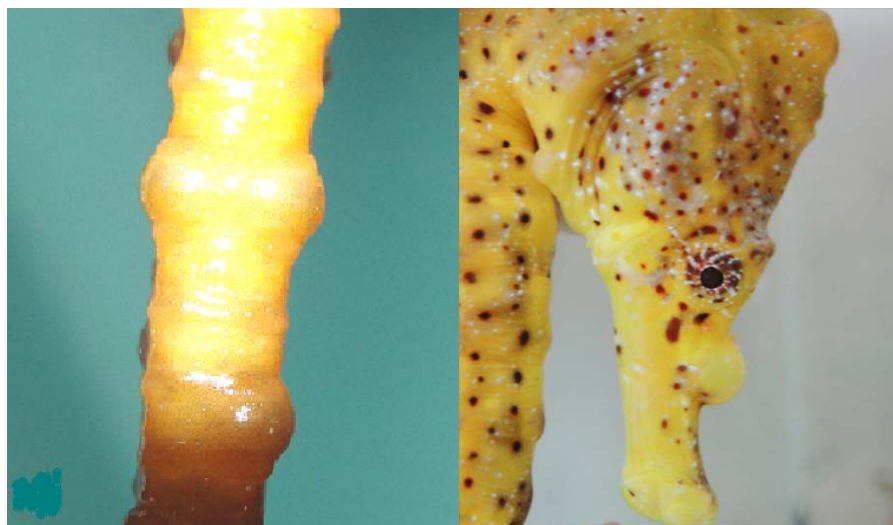

Fig. 2. External gas bubble disease observed in adult seahorse

The gas bubbles appeared on the prehensile tail and snout of seahorses is shown in Fig.2. Gasses trapped beneath the skin are believed to be caused by either bacterial infection, by air bubbles in the water column, or by gas super saturation in the water column, though this remains unresolved.

### ***Treatment***

Acetazolamide (trade name 'Diamox<sup>®</sup>'), is a non bacteriostatic sulphonamide was used to treat external gasbubble disease in seahorse. Diamox neither kill bacteria as the bacteriocidal potentiated sulfas will, nor inhibit the growth of bacteria as with the bacteriostatic sulfa drug such as sulfathizole. Rather it inhibits production of the zinc containing enzyme carbonic anhydrase which helps to control production and accumulation of carbonic anhydrase which found in most vascular part (tail and brood pouch) of seahorse. The infested seahorses were separated to hospital tank (100 lit capacity) filled with same rearing tank water and provided with nylon rope (4 mm dia) as holdfast. A 250 mg Diamox<sup>®</sup> tablet which available at local medical shop was used to treat the infected seahorses. Whole tablet was crushed into fine powder and mixed properly in beaker with some seawater. Stir well to complete dissolve the powder, the dissolved solution added to hospital tank and undisclosed tablet residues were through out. Moderate aeration was provided for proper mixing of solution in all over the tank. After 24 hours 80% water changed and replaced with fresh sea water. Care was taken to avoid difference in water quality. Then fresh solution of Diamox<sup>®</sup> was prepared and added into the tank as mentioned above and this process was repeated for 3-5 days.

### ***Deep skin ulcer in H. kuda***

A single male specimen of the captive reared spotted yellow seahorse, *H. kuda*, was observed lying dormant at the bottom of the rearing tank. Upon closer examination, it was documented with a necrotic lesion (~ 4mm dia) was present below the dorsal fin and slightly above the brood pouch. Therefore subsequent studies were carried out to check for the presence of microbial contamination of the lesion, Fig.3. The infected seahorse was then transferred into hospital tank (~ 70 lit) containing fresh filtered UV treated seawater. After microbial analysis, it was observed that out of the 7 isolates, 3 were characterized as to the genus *Vibrio* while another isolate was classified as *Photobacterium*, a member of the Vibrionaceae family. Besides *Pseudomonas* and *Bacillus* were also identified. Since the causative organisms were isolated from the necrotic lesion, for future treatment purposes an antibiotic susceptibility test was performed using motley of antibiotics to check the resistance/susceptibility of the organisms. The resistance/susceptibility of the microbes was then scored with a standard reference. The antibiotic sensitivity test revealed that all isolates tested were sensitive towards Chloramphenicol and uniformly resistant towards Tetracycline, Oxytetracycline and Nalidixic acid.

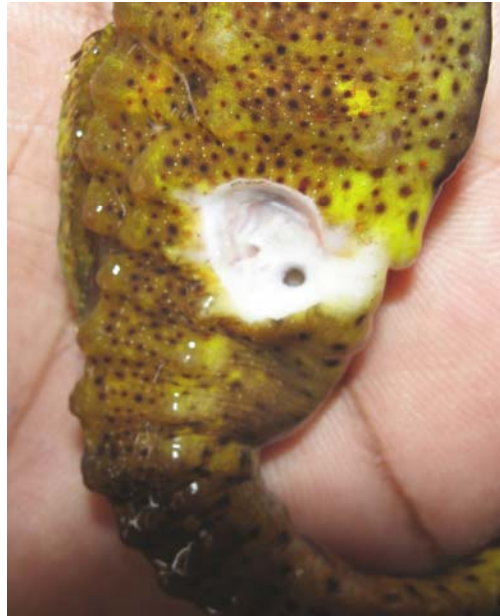

Fig. 3. Deep skin ulcer in Captive *H. kuda*

### **Parasitic infections**

#### ***Parasitic infection of marine ich, Cryptocaryon irritans***

The outbreak of parasite protozoan ciliates, *Cryptocaryon irritans*, Brown 1951 were noticed during the rearing period which leads to mass mortality of seahorses. *Cryptocaryon irritans* is a holotrichous ciliate that parasitizes marine fishes in temperate and tropical seas. *Cryptocaryon irritans* invades the epithelium of the skin and gills of fish and affects the physiological function of these organs. Its life cycle includes 3 main stages. The parasitic stage (trophont) lives embedded in the host's skin and feeds on tissue debris and body fluids; the mature trophont leaves the host, adheres to the substrate, encysts and begins to reproduce (tomont); after several divisions, the cyst ruptures, releasing the infective stage (tomites).

The clinical signs of cryptocaryonosis in marine fishes include pinhead-sized whitish nodules, mucus hyper production, skin discoloration, anorexia and respiratory distress. Infected fishes can exhibit behavioural changes, presumably due to pruritus, such as skin tremors, hyperactivity and sudden darting movements. External symptoms observed in infected seahorses includes, fish become lethargic and hover just beneath the water surface. Rapid breathing and expulsion of water in a forceful manner through the opercular opening or the mouth. Repeatedly rubbing head portions by tail with fast up-down movement. Loss of appetite. In most cases outbreak come into notice at final heavy infestation. Mortality observed in 2-3 days after visible external symptoms.

## Treatment

*Cryptocaryon irritans* have largely been confined to the examination of infections of captive fish after the parasite has been introduced into aquaria or a maniculture facility, often by an unknown source. Indeed, the presence of *C. irritans* is usually detected only after its numbers have built up on confined fish, and the original source of infection in these cases is often a matter of speculation. There is no attack of parasites on other organs of host like intestines, kidneys except gills. Formaline bath treatment (15-20 ppm) found to be very effective in treating this ectoparasite which mainly in the cyst form i.e. tomont and after develop into trophonts which attached to gills or body and fed on gill tissues of seahorse. Eradication of *Cryptocaryon initans* was also achieved through switching seahorses between 2 tanks. Weekly switches were needed, the tanks being dried and cleaned between uses. Freshwater bath for 10-15 min. also proved to be helpful before transferring into new tanks.




Fig. 4. The parasite ciliates, *Cryptocaryon irritans* isolated from the seahorse gills (a) cyst under microscope, division inside the cyst into hundreds of daughter parasites, called tomites, begins shortly thereafter, (b) Scanning Electron micrograph (SEM) of single cyst

Seahorse aquaculture face unique challenges for health care due to their anatomy and behaviour. Because of its hard and bony-plated body injections are difficult in addition to that; the semi-closed branchial chambers make gill biopsies prohibitive (Koldewey and Martin-Smith 2010). The best way to manage disease is through prevention and quarantining of new animals arriving at the culture facility should be carried out as routine. The provision of optimal environmental parameters with a good diet will also reduce health problems. It is clear that the lack of information on the treatment of the common diseases experienced in seahorse culture is a major constraint to the viability of seahorse culture and more research is urgently required (Koldewey and Martin-Smith 2010).

## Acknowledgement

The authors are grateful to Dr. Satish R. Shetye, Director, National Institute of Oceanography (CSIR), Goa, India, for encouragement and facilities. Financial support was provided by the Department of Biotechnology, New Delhi (Govt. of India).

## References

KOLDEWEY H. J. AND MARTIN-SMITH K.M. (2010). A global review of seahorse aquaculture. *Aquaculture* **302**, 131–152.

PAWAR, H. B., SANAYE, S.V., MURUGAN, A., SREEPADA, R. A. AND TANU. (2011). Effect of tank background colour on the growth and survival of juvenile yellow seahorse, *Hippocampus kuda* (Bleeker, 1852) in the pelagic phase. *The Israeli Journal of Aquaculture – Bamidgeh*, **63(4)** IIC:63.2011.621.

SNIESZKO, S.F. (1974). The effects of environmental stress on outbreaks of infectious diseases of fish. *Journal of Fish Biology* **6**, 197–208.

VINCENT, A.C.J. (1996). The international trade in seahorse. *TRAFFIC Int.*, Cambridge, p. 4.