

Effectiveness of Formaldehyde in *Caligus* Infection of Laboratory Reared Grey Mullet, *Mugil cephalus* (L)

A CHATTERJI, B S INGOLE & A H PARULEKAR

National Institute of Oceanography, Dona Paula, Goa 403 004

Received 9 July 1982; revised received 13 September 1982

Mortality due to infection by a copepod ectoparasite, *Caligus bombayensis* (R) was recorded in laboratory reared grey mullet. Spread of infection was rapid and most of infected fish died within 4 days and the entire batch died in 6-10 days. Treatment with 0.02% formaldehyde solution was effective in eradicating the infection.

For successful fish farming it is important to protect the culturable stock from various vectors and infections. Sometimes the whole population is destroyed due to an outbreak of parasitic infection. Thus, the protection of cultivated fishes from various parasitic infections needs due consideration. Information on the control of parasitic infection is mainly confined to fresh-water fishes. Diseases spread by various parasites in brackish water fishes, have not received much attention^{1,2}. Some chemotherapeutic treatments have also been evolved for the prevention and control of parasites by spraying various chemicals directly over the brackish water ponds³⁻⁵. The chances of parasitism are much more higher when a fish is reared or grown under confinement or under partially controlled environmental condition in a tank or pond.

In the present paper, a method using formaldehyde is being reported for the eradication of copepod ectoparasite, *Caligus bombayensis* (R) infesting the laboratory reared grey mullet, *Mugil cephalus* (L).

Fingerlings, 15-20 mm size, of grey mullet were collected from the mouth of the Mandovi estuary (lat. 15°28' N; long. 73°47' E). The fish in batch of 20 each were stocked in 5 different fibre glass tanks (1.2 m³) with a continuous flow of seawater (180 l/hr). During the experiments, all the fish were fed on artificial diet consisting of rice bran, treated thrash fish, dry seaweed (*Sargassum ilicifolium*) powder and wheat flour (50:40:5:5). Uneaten food and faecal matter was siphoned out, daily.

The fish were treated as follows:

Tanks 1 and 2—Fish were stocked in these 2 tanks without any prior treatment. As soon as mortality due to infection by parasites was observed, the batch of fish from Tank 1 were treated for 1 min with 0.02% formaldehyde solution on the 8th day, whereas the fish of Tank 2 were left untreated.

Tanks 3 to 5—The fish to be stocked in these tanks were first given a dip for 1 min in 0.02% formaldehyde

solution immediately after the collection and then transferred to the respective experimental tanks. Two mullets heavily infected with *C. bombayensis* were introduced, one each in Tanks 3 and 4, on the same day. As soon as mortality was observed, the mullets in Tank 4 were given a dip for 1 min in 0.02% formaldehyde solution in a separate plastic bucket. The fish of Tank 3 were not given any treatment whereas the fish in Tank 4 were left undisturbed for further observations.

A separate experiment was also carried out on 4 different batches of 20 specimens each just to find out the suitability and effectiveness of formaldehyde concentrations. Fish were treated in different concentrations of formaldehyde for different time interval. Probit regression against concentrations was made for each time interval and LC₅₀ values were calculated. A computerised Probit analysis was also carried out after correcting the percent mortality.

C. bombayensis (Fig. 1), 3.5-4 mm in size was reported for the first time on grey mullet by Rangnekar⁶. The infection caused by the parasite resulted in shedding of scales and exposing soft tissues (Fig. 2 a and b); cornea turning somewhat milky and eye ball getting loosened (Fig. 2c). A deformity in the caudal fin was also observed (Fig. 2d). In heavily infected fish, mortality was observed even within 3-5 hr.

Tank 1—Mortality in this was recorded from 4th day (Fig. 3) and 50% of the fish died on the 7th day (Fig. 4). After treatment with 0.02% formaldehyde solution, no mortality occurred from the 8th day. However, only 1 fish was found dead on the 10th day (Fig. 3).

Tank 2—As the fish were not given any formaldehyde treatment, mortality started on the 3rd day (Fig. 3) and 50% of the fish died on 7th day (Fig. 4). The remaining fish died on the 10th day (Fig. 3).

Tank 3—After the introduction of an infected grey

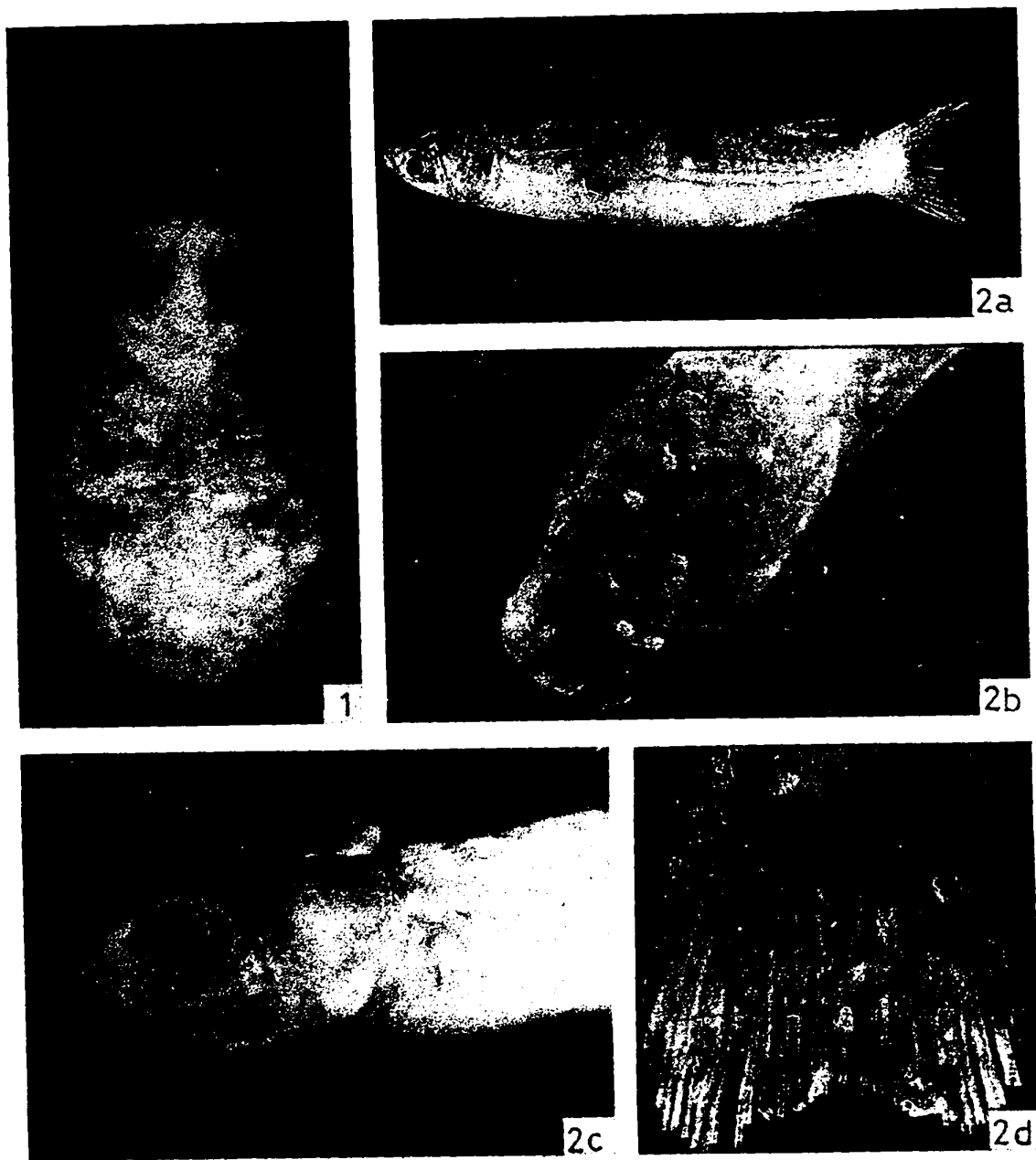


Fig. 1—*C. bombayensis* isolated from grey mullet (Dorsal view and morphological features). Fig. 2—(a) Infected grey mullet showing (1) shedding of scales; (b) head of infected mullet showing the parasite; (c) cornea of grey mullet after infection with *C. bombayensis*; and (d) deformed caudal fin of infected grey mullet.

Table 1—Derived Lethal Concentrations of Formaldehyde Solution, Slopes and Intercepts of Probit Regression Lines

Time (min)	LC ₅₀ and 95% confidence limits	Slope and 95% confidence limits	Intercept
1	0.043 (0.000376-0.000480)	5.5755(4.278-6.873)	12.6471
2	0.034 (0.000313-0.000373)	10.7795 (9.032-12.527)	20.8066
3	0.022 (0.000199-0.000242)	11.1362 (9.053-13.219)	23.4677
4	0.020 (0.000185-0.000213)	20.7510 (15.773-25.729)	40.3203

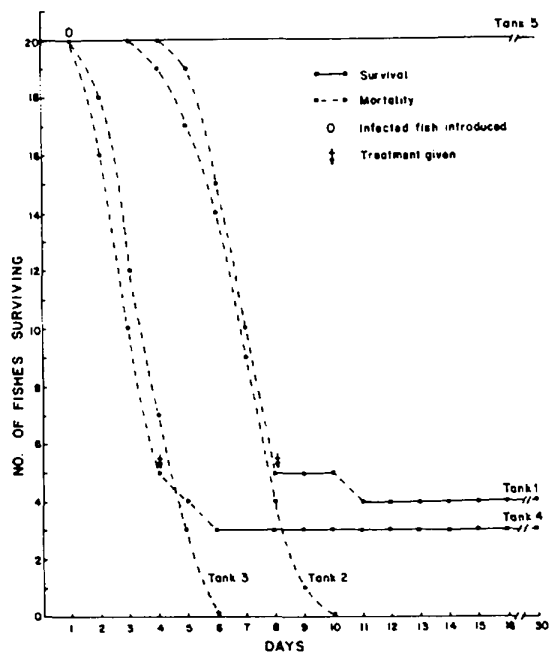


Fig. 3—Survival of juvenile grey mullet in experimental tanks 1-5

mullet the intensity of infection was so high that the whole batch of fish died within 6 days (Fig. 3).

Tank 4—The parasitic infection was eradicated at the beginning of the treatment with formaldehyde solution. Mortality in this tank was recorded only after the introduction of infected grey mullet when 50% of the population died on the 3rd day (Fig. 4). Mortality was completely averted from 4th day on treatment with 0.02% formaldehyde solution (Fig. 3).

Tank 5—No mortality was recorded in this tank indicating complete eradication of the parasite (Fig. 3).

Derived LC₅₀ values, slope and intercept of the

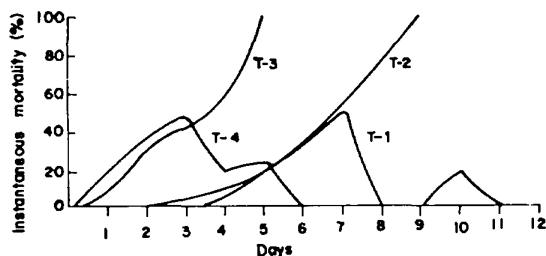


Fig. 4—Instantaneous mortality in grey mullet and infection control after treatment with formaldehyde solution

individual regression lines are shown in Table 1. Formaldehyde solution at 0.02% conc was most effective in eradicating the parasite.

Treatment with formaldehyde solution can be effective only in small populations while effective measures are needed for the eradication of infection and control of mass mortality in large scale fish culture.

The authors are thankful to Dr V V R Varadachari, Director for facilities and Dr T S S Rao, Head, Biological Oceanography Division for offering comments on the manuscript. One of the authors (AC) is thankful to CSIR, New Delhi, for the award of Research Associateship.

References

- Sindermann C J, *Principal diseases of marine fish and shell fish* (Academic Press, New York) 1970, 369.
- Ghittino P, *Riv Ital Piscic Ittiopatol*, **9** (1974) 51.
- Kabata Z, in *Diseases of Fishes Vol 2*, edited by S F Sniescs & H R Axclrod (T F H Pub Inc, Neptune City, NJ) 1970, 171.
- Sarig S, *The prevention and treatment of diseases of warmwater fishes under subtropical conditions with special emphasis on intensive fish farming* (T F H Pub Inc, Neptune City, NJ) 1971, 127.
- Hoffman G L, *Trans Am Fish Soc*, **103** (1974) 4541.
- Rangnekar M P, *J Univ Bombay*, **24** (1955) 55.