

Disease symptoms and growth performance of grey mullet infected with *Myroides odoratimimus*

Chinnarajan Ravindran*, Logeshwaran Vasudevan, Vinoth Kannan,

Biological Oceanography Division
CSIR-National Institute of Oceanography
Dona Paulo-403004

Goa

*Email: cravindran@nio.org

Phone: (+91) 832-2450442; FAX : (+91) 832-2450606

Running title: Pathogenic effects of *Myroides odoratimimus*

Key words: Blood cells, Disease symptoms, *Myroides*, *Mugil cephalus*, Pathogen.

Abstract

Myroides odoratimimus behave as low-grade opportunistic human pathogen, was isolated from the gut of moribund farmed grey mullet, *Mugil cephalus*. In the present study an experimental infection with an isolated strain of *M.odoratimimus* (NIOCR-12) was performed in *Mugil cephalus* juveniles. Growth performance, hematological parameters, histopathological and clinical symptoms were studied. The results showed a reduction in growth and an increase in the number of erythrocytes and defense cells in infected fish. Inoculated juveniles showed disease signs such as anorexia, skin hemorrhage, reddening eyes and external black patches. Furthermore histopathology analysis detected damages in infected gills and epidermis specimens. All these symptoms were similar to those described in naturally infected fish.

Bacterial diseases produce heavy mortalities in fish aquaculture in general caused by opportunistic pathogens, especially in stress culture conditions. The grey mullet *Mugil cephalus* is a euryhaline marine teleost, with benthic feeding behaviour widely cultured in brackish and fresh water semi-intensive fishponds. Its feeding behaviour is possible due to its thick-walled gizzard-like segments in their stomach along with a long gastrointestinal tract that enables them to feed on detritus (Cardona *et al.* 2000). Fish gastrointestinal tract together with skin and gills constitutes one of the major infection routes and allows a favorable condition for bacteria proliferation (Gerritsen *et al.* 2011). In this sense it was isolated a bacteria, characterized as *Myroides odoratimimus* NIOCR-12 at the government fish farm, (Old Goa, India) from the gut of moribund farmed grey mullet collected from the back waters of the facilities (Ravindran *et al.*, 2015). The present study reports the growth performance, hematological parameters, histopathological and clinical symptoms of *Mugil cephalus* juveniles challenged intraperitoneally with *M.odoratimimus*.

The bacterial dose (1.3×10^7 cfu mL⁻¹) was chosen based on lethal dose 50 (LD50) (Ravindran *et al.*, 2015) and determined by plate counting. Control group was inoculated intraperitoneally only with the saline solution. The presence of disease symptoms like anorexia, skin hemorrhage, reddening or abdominal distension and mortality were monitored daily during 37 days. For histopathology examination dissected gills and skin tissues were fixed in 10 % neutral phosphate-buffered formalin for three days at room temperature and subsequently embedded in paraffin using a standard protocol, sectioned and stained with haematoxylin and eosin (HE) according to standard histological techniques. Single sections including gill filaments and lamellae from each infected and healthy fish were examined by light microscopy.

For haematological analysis blood samples were collected by caudal vein puncture using a sterile plastic syringe (2.5 mL) and added with EDTA as an anticoagulant agent (2.1 mg mL⁻¹). Red blood cell (RBC) and white blood cell (WBC) counts were determined using an improved Neubauerhaematocytometer and calculated. Briefly, 5 µL of peripheral whole blood was fixed and stained with 45 µL of formaldehyde containing 0.01 % (w/v) methyl violet solution in phosphate buffered saline (PBS) for at least 5 min. All data of growth, haematological parameters are presented as means \pm SD. After testing for normality an Analysis of variance was performed using Microsoft Excell 2007 (P<0.05).

Infectivity assays showed abnormalities in fish behavioral characteristics by 1-2 days post inoculation (dpi) with displayed anorexic and head up swimming with rapid breathing. During 3-5 dpi the moribund fish was observed for swimming close to the surface or stationary at bottom and lethargic activity. Skin hemorrhage and reddening were found at the eye, mouth abdomen, and

pectoral fin regions (Fig. 1a, b, c-ii, iii-) at the initial stages of infection. At an advance stage of infection, fishes presented symptoms of external black colour patches on the skin and also with eye hemorrhages (Fig. 1a, b, c-ii, iii-). *M. odoratimimus* was recovered from all target organs liver, muscle and gut of all diseased mullet, while, the bacteria was not isolated from any control fish.

Observations of challenged fish were extended to 37 days. When mullet were experimentally injected with 1.3×10^7 cfu mL⁻¹ bacteria, a total of 3 fish survived. Histopathological manifestations in the gills and skin of the sampled fish were carried out to assess the damage caused due to *M. odoratimimus* (1.3×10^7 cfu mL⁻¹). Control fish shows normal gill structure with intact primary and secondary lamellae (Fig. 2a) while diseased fish shows hyperplasia of epithelial cells lining secondary lamellae resulting in lamellar fusion (Fig. 2b). The skin of the infected fish showed severe tissue abnormalities in epidermis and dermis (Fig. 3). Clinical symptoms and histological changes of the experimental fish induced by the bacterial infection were similar to those of naturally infected fish. Furthermore, growth performance was significantly affected by the *M. odoratimimus* infection (Table 1). So infected fish showed lower weight and total length than control ones ($P < 0.05$). Thus, *M. odoratimimus* had a negative effect on the production parameters of grey mullet and consequently it could produce economic losses.

The infectious agents that stimulate defense responses through hematological cells are the well-known factors in mammals (Janeway *et al.*, 2001) and fish (Uribe *et al.*, 2011). In this context in this study we determined the blood defense cells against the pathogen infection. RBC and WBC showed alterations in infected fish in comparison to control ones (Table 2). The erythrocytes are known for their gas exchange function and they may be also involved in the immune response (Morera and Mackenzie, 2011). In this sense the results obtained in this study support this idea (Table 2). Likewise a significantly higher level of all of the WBC was found in infected fish. In this context a higher level of neutrophils and lymphocytes is generally related to disease and inflammatory responses respectively (Sebastiao *et al.*, 2011). Additionally the higher level of monocytes detected in infected fish may denote a greater activation of the defense mechanism in comparison to control fish. Our results agree with those reported by other authors in *Oreochromis niloticus* (Sebastiao *et al.*, 2011) and in *Carassius auratus* (Grayferet *et al.*, 2010).

In short *M. odoratimimus* that has been isolated from the gut of moribund farmed *M. cephalus*, may cause significant changes in the haematological characteristics and productive performance of grey mullet. This bacterial strain has been previously described as human pathogen too. In this sense the results obtained in this study denote that *M. cephalus* may act as a vector transferring *M. odoratimimus* from specimens to humans. More studies should be carried out in the

future to determine the zoonotic potential of this bacterial species. Furthermore *M. odoratimimus* may cause serious economic losses in grey mullet production due to severe reduction in fish growth.

Acknowledgements

Authors thank Director, CSIR-National Institute of Oceanography (NIO), Goa, India for providing the lab facilities and support. Authors have no conflict of interests. Authors also thank the anonymous reviewers for their valuable suggestions in improving the manuscript.

References

- Cardona L., Gisbert E. & Torras X. (2000) Cascading effects of the flathead grey mullet *Mugil cephalus* in freshwater eutrophic microcosmos. *Hydrobiologia* **429**, 49–57.
- Gerritsen J., Smidt H., Rijkers G. T., & de Vos W. M. (2011) Intestinal microbiota in human health and disease: the impact of probiotics. *Genes and Nutrition*, **6**(3), 209–240.
- Grayfer L., Garcia E. G. & Belosevic M. (2010) Comparison of Macrophage Antimicrobial Responses Induced by Type II Interferons of the Goldfish (*Carassius auratus* L.). *The Journal of Biological Chemistry* **285**, 23537-23547.
- Janeway CA Jr., Travers P., Walport M, *et al.*, (2001) Immunobiology: The Immune System in Health and Disease. 5th edition. New York: Garland Science; 2001. The front line of host defense. Available from: <http://www.ncbi.nlm.nih.gov/books/NBK27105/>
- Morera D. & MacKenzie S.A. (2011) Is there a direct role for erythrocytes in the immune response? *Veterinary Research*. **42**, 89.
- Ravindran C., Varatharajan, G.R., Rajasabapathy, R., Logeswaran, V. & Sreepada R, A. 2015. Infection and pathogenicity of *Myroides odoratimimus* (NIOCR-12) isolated from the gut of grey mullet (*Mugil cephalus* (Linnaeus, 1758)). *Microbial Pathogenesis* **88**, 22-28.
- Sebastião F.A., Nomura D., Sakabe R. & Pilarski F. (2011) Hematology and productive performance of Nile Tilapia (*Oreochromis niloticus*) naturally infected with *Flavobacterium columnare*. *Brazilian Journal of Microbiology* **42**, 282-289
- Uribe C., Folch H., Enriquez R. & Moran G. (2011) Innate and adaptive immunity in teleost fish (a review). *Veterinarni Medicina* **56**, 486–503

Figure Legend

Fig.1. Comparison of external clinical signs in Control (i) and infected (ii and iii) *M. cephalus*:

a. Eye hemorrhage, b. Skin hemorrhage, gill, operculum and fin redness and c. Anal and caudal fin redness. (ii and iii are crescent levels of disease symptoms in infected specimens).

Fig.2. Light microscope images ($\times 40$) from gills of control and infected fish showing (a) normal gill structure with intact primary and secondary lamellae and (b) hyperplasia of epithelial cells lining secondary lamellae resulting in lamellar fusion respectively.

Fig. 3 Light microscope images ($\times 40$) of severe tissue abnormalities in epidermis and dermis of infected fish.

Figure 1

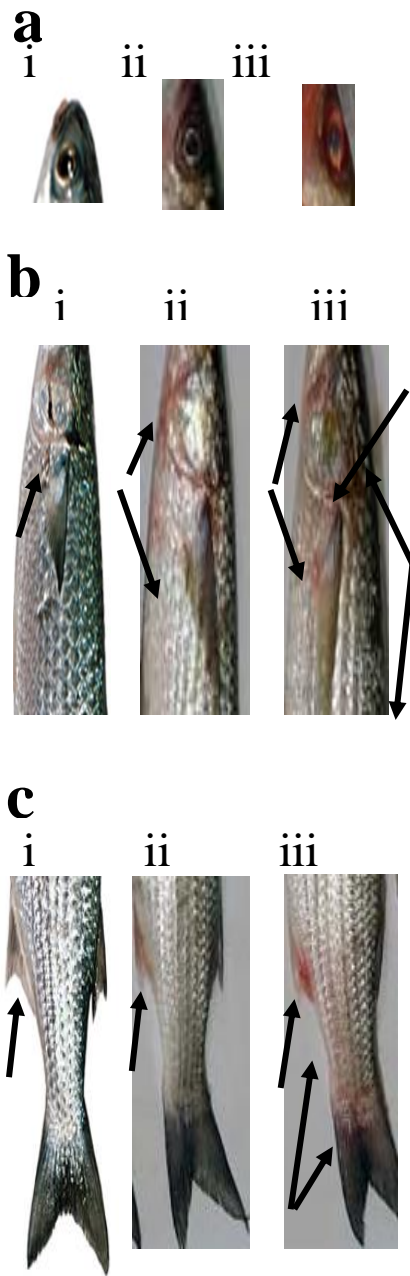


Figure 2




Figure 3

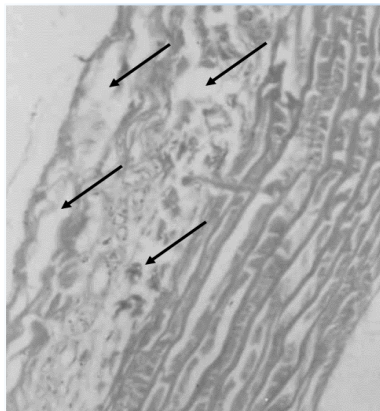


Table 1 Growth performance (Mean \pm SD) of infected and control fish after 37 days of challenge (n=10)

	Uninfected fish	Infected fish
Wet Weight (g)	24.5 \pm 0.4 (P<0.05)	23.8 \pm 0.3 (P<0.05)
Total Length (cm)	7.9 \pm 0.2 (P<0.05)	7.45 \pm 0.24 (P<0.05)

Table 2 Haematological parameters (Mean \pm SD) of infected and control fish after 37 days of challenge (n=10)

Haematological Parameters	Uninfected	Infected
Total no of fish	10	10
Erythrocyte ($\times 10^6/\mu\text{l}$)	133.7 \pm 3.3 (P<0.05)	143.7 \pm 3.5 (P<0.05)
Leukocyte (total) ($\times 10^6/\mu\text{l}$)	5.7 \pm 1.8 (P<0.05)	7.4 \pm 1.6 (P<0.05)
Lymphocytes ($\times 10^6/\mu\text{l}$)	2.5 \pm 0.8 (P<0.05)	3.4 \pm 0.5 (P<0.05)
Neutrophils ($\times 10^6/\mu\text{l}$)	1.2 \pm 0.7 (P<0.05)	2.2 \pm 0.7 (P<0.05)
Monocytes ($\times 10^6/\mu\text{l}$)	0.9 \pm 1.2 (P<0.05)	1.2 \pm 0.8 (P<0.05)